

# Benefits of Using Telemedicine in Glaucoma Screening and Early Diagnostics

G.Markauskiene<sup>1</sup>, V.Graziene<sup>2</sup>, K.Andrijauskas<sup>3</sup>, J.Bernataviciene<sup>4</sup>, P.Treigys<sup>4</sup>, A.Paunksnis<sup>5</sup>

1 - Hospital of Lithuanian University of Health Sciences, 2- Kedainiai City Hospital, Lithuania; 3 – Lithuanian University of Health Sciences, Lithuania, 4 – Institute of Mathematics and Informatics of Vilnius University, Lithuania, 5 – Telemedicine Research Centre, Lithuania

## Purpose

- To determine benefits of using telemedicine in glaucoma screening with the aim of early diagnostics of glaucoma.

## Hypothesis

- Screenings using telemedicine and portable diagnostic devices at remote locations can be effectively used for early diagnostics of glaucoma
- Tertiary level of health care can be brought to the primary level of health care using appropriate high quality technology and methods.

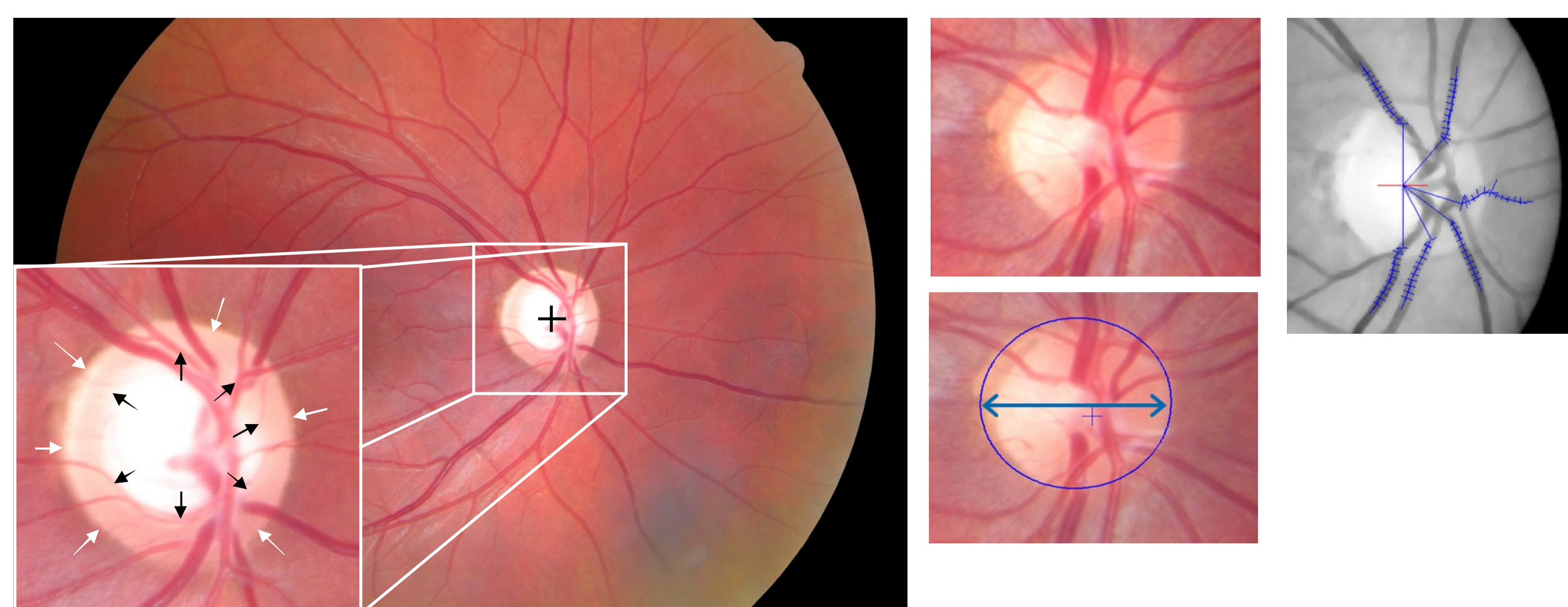
## Technology Used



- Smartscope Digital Eye Fundus Camera by Optomed OY (Finland).

Technical features:

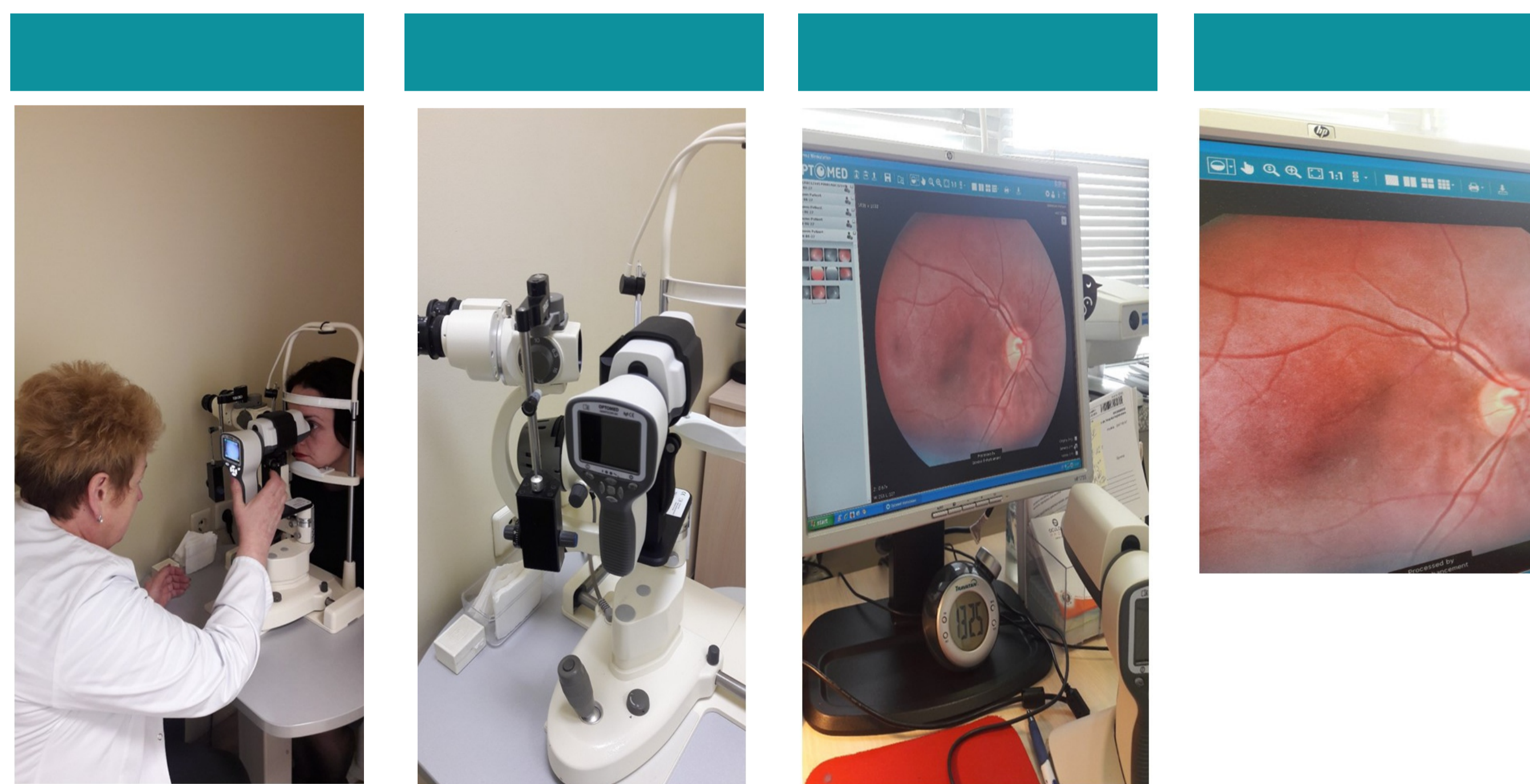- High Resolution.
- Portability.
- Easy Connectivity (USB, Wi-Fi).
- Image Storing.
- Software filters for image enhancement.



## Methods

- Active preventive screening was performed for 530 patients of age 35-65 at primary health care centers in 5 remote areas of Lithuania over 5 years. Patients' visual acuity, intraocular pressure were tested, eye fundus image was taken and sent for specialist ophthalmologist evaluation. Optic nerve head measurement algorithm was used at screening. Digital handheld non-mydratic eye fundus camera Smartscope M5 PRO (Optomed OY, Finland) was used in this study for obtaining images of the optical nerve head and transmission for specialist consultations. Different stages of glaucoma were compared within this study (early; advanced; late stage). Patient satisfaction was surveyed as part of this study.

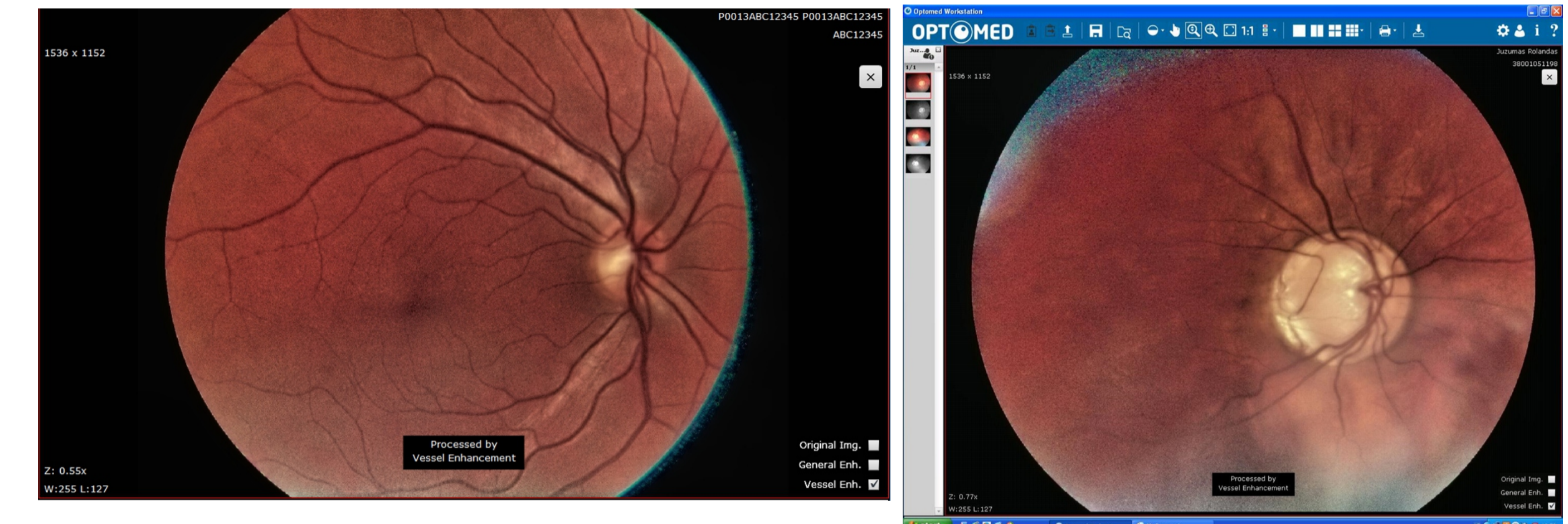
## Procedure



## Results

- 530 patients were screened, 1060 eye fundus images obtained. Based on the evaluation of eye fundus and optical nerve head, if glaucoma was suspected, additional tests were performed at the tertiary level health care institution. Of the 530 patients, there were 50 cases of suspected glaucoma. In 6% of cases of all patients, early glaucoma was diagnosed and timely treatment plan started..

## Imaging Results



High quality storable and transmittable eye fundus images

## Conclusion

- Screenings using telemedicine at remote locations with “traditional” screenings at a tertiary level health care institution showed that telemedicine, employing advanced high quality image technology and trained medical personnel at primary level health care institutions, can be effectively used for early diagnostics of glaucoma. Based on patient satisfaction surveys, virtually 100% of patients expressed satisfaction with the screenings near their home using telemedicine and would like them to be permanently continued. The waiting time for specialist consultation gets reduced by three months.

## References

1. G. Michelson (Ed.) Teleophthalmology in Preventive Medicine. Springer Verlag: Berlin and Heidelberg, 2015;
2. N. G. Strouthidis, G Chandrasekharan, J. P. Diamond, I. E. Murdoch, Teleglaucoma: Ready to Go? *British Journal of Ophthalmology*, 2014, 98, 12, 1605.