

Case Report

Surgical Repair of the Extrusion of the Body of a PAUL Implant for Glaucoma

Elena Milla^a Jordi Izquierdo^a Bernardo Sanchez Dalmau^b

^aGlaucoma Unit, Hospital Clinic, Barcelona University, Barcelona, Spain;

^bNeuro Ophthalmology Unit, Hospital Clinic, Barcelona, Spain

Keywords

Glaucoma surgery · Glaucoma PAUL implant · Extrusion · Case report

Abstract

The purpose of our article was to describe a simple but effective surgical technique performed on a patient with an extrusion of part of the body of a PAUL drainage implant for glaucoma. We present the case of a patient with refractory glaucoma and a history of multiple ocular interventions. A PAUL shunt was implanted and in the early postoperative period the patient presented extrusion of part of the implant body. An excessive scarring tissue at the lateral rectus muscle tendon hampered the placement of the lateral wing under the muscle; therefore, we decided to trim a part of it and suture the implant body to the sclera. The surgical technique that satisfactorily resolved the complication is described and shown in a video. This is the first time that such complication is described with the PAUL implant. We suggest that the intrinsic characteristics of the implant, mainly the dimensions, material, and thickness, made it possible for a potentially serious complication such as that described to be solved in a relatively simple and nontraumatic way for the eye.

© 2022 The Author(s).

Published by S. Karger AG, Basel

Background

Glaucoma drainage devices (GDDs) have proven their strength and place in the surgical treatment of glaucoma, both in primary open-angle glaucoma with or without previous surgery [1] and in refractory and secondary glaucoma [2]. The different designs and advances in this surgical technique, both in the location of the plates and the access to the interior of the eye, have incorporated variations that improve the safety and efficacy of the technique, allowing surgical strategies to be decided individually.

Correspondence to:
Elena Milla, millagrinoelena@gmail.com

GDD is indicated when it is assumed that risk factors for scarring mean a bleb-forming surgery is not recommended. In addition, surgery with GDD is versatile in terms of size and location and adaptable to the extreme conditions of the eyeball. Therefore, they are optimal for cases with a poor prognosis for bleb-forming techniques as the GDD filter capsule has a different structure and behavior to that of filtering bleb surgeries [3].

The type of implant chosen depends on the priorities of the surgical technique and the objectives to be achieved. The greater safety and postoperative comfort of valved GDD contrasts with the greater hypotensive efficacy of nonvalved GDD [4], which requires perioperative maneuvers to regulate the intraocular pressure (IOP) during the immediate postoperative period or the introduction of flow pressure control devices like eyeWatch™, which varies the diameter of the extraocular tube through a magnetic externally controlled device [5]. The preoperative plan must individually assess the pros and cons of each option to decide the type of implant, the specific access, the location of the plates, and the flow control measurements to be used. The success of a GDD depends, like most glaucoma surgeries, on the postoperative management. Patients with an intracameral tube require long-term periodic control of the position of the intraocular tube and the endothelial state, and there is also a threat of extrusion or exposure of the extraocular portion of these implants.

The PAUL Glaucoma Implant (PGI) (Advanced Ophthalmic Innovations, Singapore, Republic of Singapore) is a novel shunt manufactured from medical-grade silicone that is differentiated from other currently available options in that both the external tube diameter of 467 μm and the internal diameter of 127 μm are smaller (in contrast with Ahmed, double Molteno or Baerveldt implants with an external and internal shunt diameters of 600 μm and 300 μm , respectively) and thereby occupy less space in the anterior chamber angle while preserving a large-surface area end plate for aqueous absorption (342 mm^2). Although the PGI has a smaller tube with less redundant flow capacity than other nonvalved tubes like the Baerveldt implant, it is still large enough to provide only minimal resistance to aqueous outflow. The smaller tube should, theoretically, reduce the risk of corneal endothelial contact and damage at the entry site, especially in eyes with smaller anterior segments or shallower anterior chambers.

An advantage of the smaller internal caliber is that early postoperative hypotony can be prevented using a much smaller ripcord than the Baerveldt implant, potentially resulting in less variability [6]. The PGI is made of very flexible silicone that facilitates its folding and mobilization to place it below the rectus muscles without requiring a large conjunctival opening, which is of interest, since they are usually cases with poor-quality conjunctivae as they are multi-operated eyes, and the subsequent closure and healing of the wound are sometimes difficult. The advent of minimally invasive glaucoma surgery has promoted GDD designs that facilitate less invasiveness and greater respect for the tissue. However, no surgical technique, no matter how less invasive, is free of complications and unexpected events, even though the surgical technique is correct and meticulous.

Case Presentation

We report the case of a 73-year-old male with a history of primary open-angle glaucoma refractory to medical treatment who had previously undergone glaucoma filtering surgery (nonpenetrating deep sclerectomy with subsequent needling maneuvers and major review of the bleb in the operating room) 2 years previously and vitrectomy in the right eye due to an epiretinal membrane 3 years previously. The patient presented no notable systemic diseases or treatment with antiplatelet drugs, anticoagulants, or other medications of interest. The visual acuity was 6/9.5, and the patient was pseudophakic with a flattened filtration bleb and an IOP of 26 mm Hg with the maximum tolerated medication (three active principles and

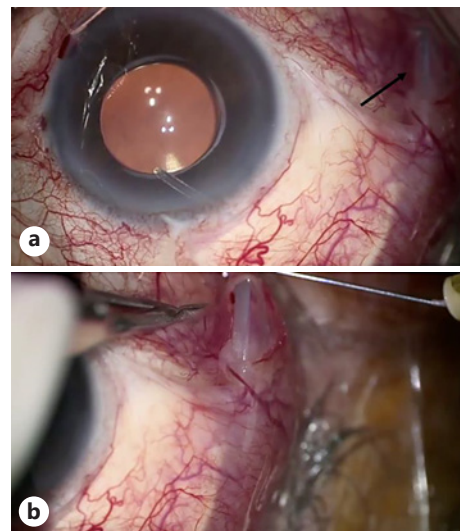


Fig. 1. **a** The arrow shows the exposure of the lateral flap of the PGI through the conjunctiva and elongation of the tube in the anterior chamber. **b** View of the area of shunt extrusion during anesthesia.

250 mg oral acetazolamide daily). The optic nerve head showed an excavation of 0.8 with severe inferior visual field defect. The conjunctiva was hyperemic and showed very poor mobility. Therefore, it was decided to implant a PGI in the superior temporal quadrant of the eye. The intervention presented no notable incidents. The implant was placed under the upper and lateral rectus muscles and fixed to the sclera with nylon 9/0; the tube partially occluded with a prolene 6/0 suture, whose distal end was placed in the lower subconjunctival area with the tube being introduced into the anterior chamber near the iris. The extraocular tube portion was coated with donor sclera and fixed by applying biological tissue glue composed of plasminogen and fibrinogen. The conjunctival closure was performed with a self-lock running suture with 8/0 silk. The scleral surface was treated with 5-fluouracil embedded in a surgical sponge prior to implant placement, as we routinely perform in cases at high risk of fibrosis.

At 24 h, the eye presented a wide anterior chamber (grade IV), without hyphema, no aqueous humor leakage, preserved visual acuity, and IOP of 8 mm Hg without topical hypotensive treatment. Treatment consisted of topical dexamethasone every 3 h and topical antibiotic every 6 h, which was withdrawn 1 week postoperatively. A month after surgery, the IOP was 8 mm Hg and the rest of the examination was normal, so it was decided not to withdraw the intraluminal suture for the time being and to continue with topical cortisone treatment only.

The patient did not attend some postoperative visits due to the COVID 19 pandemic and 3 months after surgery presented with a partial extrusion of the lateral wing of the PGI that appeared through the conjunctiva, with wound leakage and IOP of 5 mm Hg, despite which he did not present clinical manifestations of hypotony in the anterior or posterior poles. There was excessive penetration of the tube in the anterior chamber due to dislocation of the implant (Fig. 1a, b). Therefore, the patient was scheduled for surgical revision (online suppl. Video; for all online suppl. material, see www.karger.com/doi/10.1159/000525985). The patient received topical anesthesia with 5% lidocaine drops and subconjunctival injection of 2% lidocaine with epinephrine to produce vasoconstriction.

Repeat surgery showed a cyst in the tendon of the lateral rectus muscle accompanied by scarring tissue, which had caused the dislocation of the lateral flap of the PGI toward the subconjunctival space, with consequent erosion of the overlying conjunctiva and extrusion of the implant. The lateral rectus muscle was dissected carefully since it was attached to both the subconjunctiva and the episclera. Two strabismus hooks were used to longitudinally

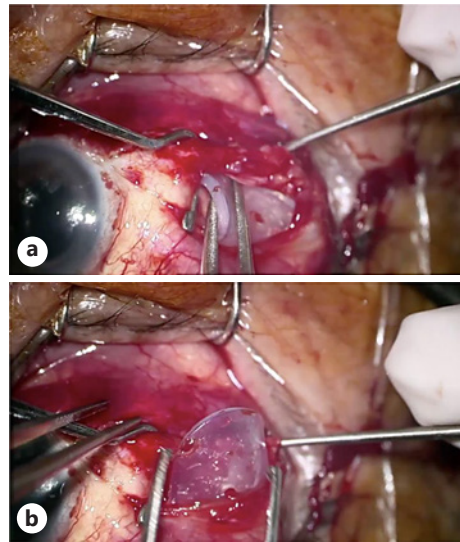


Fig. 2. **a** The lateral rectus muscle was dissected with two hooks while trying to slide the implant flap under the muscle. **b** The PGI flap bounced and was extruded again.

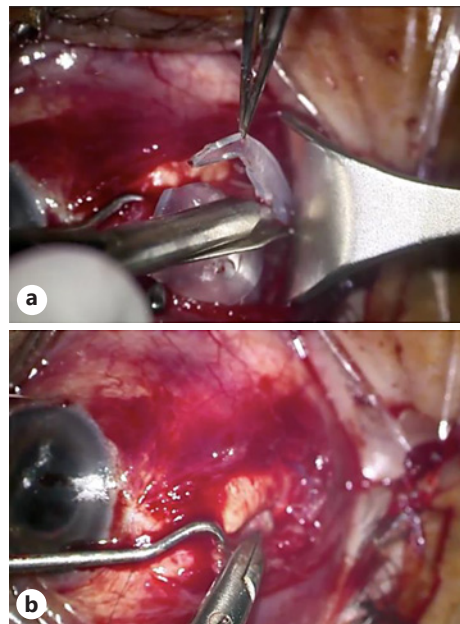


Fig. 3. **a** The right contour of the implant was trimmed to refine its tip and enable it to fit under the muscle. **b** The tip of the trimmed flap is sutured to the sclera with 9/0 nylon and the implant remained stable in this position.

dissect the muscular body. However, on repeated occasions, when trying to slide the implant wing under the muscle, it bounced and was extruded again (Fig. 2a, b). Finally, it was decided to trim a portion of the upper and lower area of the implant wing with Westcott scissors to make it more elongated and reduce its diameter, and this finally allowed stable placement below the muscle. However, given the degree of muscle fibrosis, it was decided to suture the body of the implant to the sclera to achieve greater stability (Fig. 3a, b) with three 9/0 nylon sutures. Subsequently, the ripcord was placed again subconjunctivally in the lower temporal quadrant and a careful closure was carried out using Tenon (vicryl 8/0) and conjunctival planes with continuous suture (silk 8/0).

In subsequent visits, the implant has remained well positioned without presenting extrusions or dislocations and the IOP is around 12 mm Hg without additional hypotensive medication. At 6 months after surgery, the intraluminal ripcord has not yet been removed.

Discussion and Conclusions

The use of GDD has increased significantly in recent years for both the primary treatment of glaucoma and refractory glaucoma. The efficacy and safety of GDD is well established, so they are a viable surgical option in patients who fail medical therapy. With the increased use of these devices, understanding their complications is essential in managing these patients.

Traditionally, GDD has been used for refractory cases, but recently they have become more popular due to their safe and versatile nature. Several devices with subtypes have been developed. The most popular devices currently include the Molteno, Baerveldt, and Ahmed Clear Path nonvalved implants and the Ahmed valved device.

Although the Tube versus Trabeculectomy Study (TVT) showed a lower rate of complications with tubes compared with trabeculectomies [3], the possibilities of adverse outcomes with tube implantation remain [7]. Understanding the possible complications associated with GDD is essential for ophthalmologists, both with and without specific glaucoma training.

The erosion or extrusion of a GDD is a serious complication unique to this specific surgery. It poses an increased risk of endophthalmitis due to the exposure of the shunt connected with the anterior chamber. The incidence of endophthalmitis after GDD implantation in one study was 9 out of 542 eyes. Of the 9 cases, 6 had tube erosion. In some cases, when this complication occurs, despite prior repair, the device simply needs to be removed [8].

In the surgical series of patients receiving PGI, the extrusion of the body of the implant has not been described yet [9]. In the PAUL Glaucoma Implant Study Group series [6], 4.1% of patients presented an exposure of the tube. It is a more common complication than the extrusion of the body in GDD in general, and much easier to solve, since it simply requires a new coverage with tissues such as donor sclera, cornea, fascia lata, bovine pericardium, etc. [10]. In our case, it was the exposure of an area of the implant body due to the formation of a cyst in the tendon of the lateral rectus muscle and progressive fibrosis and shortening of the muscle that was progressively expelling the implant flap out and up. When this flap was housed in the subconjunctival space, the consequent conjunctival erosion occurred. We believe that the patient presented an excessive scarring tissue at the lateral muscle tendon due to the repeated previous operations that traumatized this area. In these multi-operated cases, we routinely use intraoperative antimetabolites, mainly 5-fluouracil, but in this case, it was not sufficient to avoid progressive fibrosis. We also normally use biological glue to attach the scleral donor flap onto the tube, but we do not use this product to seal the conjunctival wound for two main reasons: first not to promote adhesions at the level of the rectus muscles and second to avoid the risk of wound dehiscence; therefore, we prefer to place an 8/0 silk self-lock running suture.

No surgical technique, no matter how minimally invasive, is free of complications, although we rigorously followed the pre-, per, and post-surgical protocol. We suggest that, given the unique characteristics of the new PGI, this serious complication could be resolved with less tissue disruption. Muscle dissection was the most complicated step, given the risk of rupture and backward retraction of the muscular body that would have required a very complicated surgery in this case of strabismus. We believe that, in this eye with such poor conjunctival quality, explanting the whole implant and placing it in another quadrant would have been even more traumatic for the eyeball. Now, we still have the upper nasal quadrant and both inferior quadrants for future surgical needs. The possibility of trimming the implant, given its smaller thickness and very flexible material, allowed customization of the size and shape to be able to adapt it perfectly to the needs

of the case and allow preservation of the implant with satisfactory IOP control. PGI has an efficient filtering area of 305.42 mm² which is the portion that lies in between the two rectus muscles and extends to the posterior part of the eyeball (in contrast with the Baerveldt implant that has a longer horizontal diameter but narrower body and thus a smaller filtering surface of 246.86 mm²). The lateral wings that are placed under the muscles are not part of the filtering surface of the implant; therefore, the fact of trimming it did not affect the overall efficacy of the device.

Statement of Ethics

The study was approved by the Ethics Committee of the Hospital Clinic de Barcelona, reference no. 02/December 10, 2021. Written informed consent was obtained from the patient for publication of the details of their medical case and any accompanying images.

Conflict of Interest Statement

The authors have no commercial interest in any of the products cited.

Funding Sources

The study has not received any funding.

Author Contributions

Elena Milla participated in the operation, follow-up of the patient, and writing the article; Jordi Izquierdo participated in the postoperative visits and data collection; and Bernardo Sanchez Dalmau contributed to the development of the surgical technique.

Data Availability Statement

All data generated or analyzed during this study are included in this published article and its online supplementary material files.

References

- 1 Gedde SJ, Feuer WJ, Lim KS, Barton K, Goyal S, Ahmed IIK, et al. Treatment outcomes in the primary tube versus trabeculectomy study after 3 years of follow-up. *Ophthalmology*. 2020;127:333–45.
- 2 Christakis PG, Zhang D, Budenz DL, Barton K, Tsai JC, Ahmed IIK, et al. Five-year pooled data analysis of the Ahmed Baerveldt comparison study and the Ahmed versus Baerveldt study. *Am J Ophthalmol*. 2017;176:118–26.
- 3 Dempster AG, Moltano ACB, Bevin TH, Thompson AM. Otago glaucoma surgery outcome study: electron microscopy of capsules around Moltano implants. *Invest Ophthalmol Vis Sci*. 2011;52(11):8300–9.
- 4 Duch S, Arciniegas-Perasso CA, Piludu S, Djavanmardi S, Milla E. Risk factors for failure in double-plate tube surgery for refractory glaucoma: 25 years surgical experience. *Clin Ophthalmol*. 2021;15:461–72.
- 5 Roy S, Villamarin A, Stergiopoulos C, Bigler S, Guidotti J, Stergiopoulos N, et al. Initial clinical results of the eyeWatch: a new adjustable glaucoma drainage device used in refractory glaucoma surgery. *J Glaucoma*. 2019;28(5):452–8.
- 6 Koh V, Chew P, Triolo G, Lim KS, Barton K, PAUL Glaucoma Implant Study Group. Treatment outcomes using the PAUL glaucoma implant to control intraocular pressure in eyes with refractory glaucoma. *Ophthalmol Glaucoma*. 2020;3(5):350–9.

- 7 Gedde SJ, Schiffman JC, Feuer WJ, Herndon LW, Brandt JD, Budenz DL, et al. Treatment outcomes in the tube versus trabeculectomy (TVT) study after five years of follow-up. *Am J Ophthalmol*. 2012;153(5):789–803.e2.
- 8 Al-Torbak AA, Al-Shahwan S, Al-Jadaan I, Al-Hommadi A, Edward DP. Endophthalmitis associated with the Ahmed glaucoma valve implant. *Br J Ophthalmol*. 2005;89(4):454–8.
- 9 Vallabh NA, Mason F, Yu JTS, Yau K, Fenerty CH, Mercieca K, et al. Surgical technique, perioperative management and early outcome data of the Paul® glaucoma drainage device. *Eye*. 2021:1–6. Epub ahead of print.
- 10 Nardi M, Maglionico MN, Posarelli C, Figus M. Managing Ahmed glaucoma valve tube exposure: surgical technique. *Eur J Ophthalmol*. 2021;31(2):778–81.